

2. *Игнатов Ю. Д.* Современные аспекты терапии боли: опыты / Ю. Д. Игнатов, А. А. Зайцев // Качественная клиническая практика. – 2001. – № 2. – С. 2–13.

3. *Zeilhofer H. U.* GABAergic analgesia: new insights from mutant mice and subtype-selective agonists / H. U. Zeilhofer, H. Mohler, A. Di Lio // Trends. Pharmacol. Sci. – 2012. – Vol. 30. – P. 397–402.

4. *The design of non-peptide human bradykinin B2 receptor antagonists employing the benzodiazepine peptidomimetic scaffold* / E. K. Dziadulewicz, M. C. Brown, A. R. Dunstan [et al.] // Bioorg. Med. Chem. Lett. – 1999. – Vol. 9. – P. 463–468.

5. *Benzodiazepines as Potent and Selective Bradykinin B1 Antagonists* / M. R. Wood, J. J. Kim, W. Han [et al.]

// J. Med. Chem. – 2003. – Vol. 46, N 10. – P. 1803–1806.

6. *Прозоровский В. Б.* Статистическая обработка результатов фармакологических исследований / В. Б. Про- зоровский // Психофармакология и биологическая наркологи́я. – 2007. – Т. 7, № 3/4. – С. 2090–2120.

7. *In vivo evaluation of substituted 3-amino-1,4-benzodiazepines as antidepressant, anxiolytic and anti-nociceptive agents* / E. Lattmann, P. Lattmann, Y. Boonprakob [et al.] // Arzneimittelforschung. – 2009. – Vol. 59, N 2. – P. 61–71.

8. *Синтез, анальгетическая и противовоспалительная активность новых производных бензодиазепина* / Н. Наджафа, М. Пирали, Р. Даулатбади [и др.] // Химико-фармакологический журнал. – 2005. – Т. 30, № 12. – С. 21–23.

9. *Пат.* 107433, МПК С07D 243/14, 243/24, 31/5513 1-алкіл-3-ацетокси-1,2-дигідро-3H-1,4-бенздіазепін-2-они як анальгетичні засоби / Павловський В. І., Андронаті С. А., Кабанова Т. А., Халімова О. І., Вороненко Є. В.; заявник та патентовласник Фізико-хімічний інститут імені О. В. Богатського НАН України. – № а201315525; заявл. 30.12.2013; опубл. 25.12.2014, Бюл. № 24.

10. *Гацура В. В.* Методы первичного фармакологического исследования биологически активных веществ / В. В. Гацура. – М.: Медицина, 1974. – С. 130.

11. *The formalin test: an evaluation of the method* / A. Tjolsen, O.-G. Berge, S. Hunskaar [et al.] // Pain. – 1992. – Vol. 51. – P. 5–17.

УДК 547.891.2:615.212+262.1

В. І. Павловський, Т. А. Кабанова, О. І. Халімова, Є. В. Вороненко С. А. Андронаті
АНАЛЬГЕТИЧНІ ВЛАСТИВОСТІ 1-АЛКІЛ-3-АЦЕТОКСИ-1,2-ДИГІДРО-3H-1,4-БЕНЗДІАЗЕПІН-2-ОНІВ

Метою даної роботи є вивчення анальгетичних властивостей раніше синтезованих 1-алкіл-3-ацетокси-1,2-дигідро-3H-1,4-бенздіазепін-2-онів.

Анальгетичну активність досліджували *in vivo* на мишах за методом «корчів», викликаних внутрішньоочеревинно введенням оцтової кислоти, і за допомогою формалінового тесту. Як препарат порівняння використовували диклофенак натрію.

Виявлено високу анальгетичну активність нових сполук ряду 1-алкіл-3-ацетокси-1,2-дигідро-3H-1,4-бенздіазепін-2-онів, показники ED₅₀ з анальгетичної активності перебувають у діапазоні від 0,058 мг/кг до 1,500 мг/кг, при цьому всі тестовані сполуки перевищували за анальгетичною активністю препарат порівняння диклофенак натрію.

Одержані дані свідчать про перспективність сполук вивченого ряду з метою пошуку та створення нових ефективних анальгетичних і протизапальних засобів.

Ключові слова: 1-алкіл-3-ацетокси-1,2-дигідро-3H-1,4-бенздіазепін-2-они, анальгезія, формаліновий тест.

UDC 547.891.2:615.212+262.1

V. I. Pavlovsky, T. A. Kabanova, O. I. Khalimova, Ye. V. Voronenko, S. A. Andronati
ANALGESIC PROPERTIES OF 1-ALKYL-3-ACETOXY-1,2-DIHYDRO-3H-1,4-BENZODIAZEPINE-2-ONES

The aim of given work is to study the analgesic properties of previously synthesized 1-alkyl-3-acetoxy-1,2-dihydro-3H-1,4-benzodiazepine-2-ones.

Analgesic activity was studied *in vivo* in mice on a model of “writhing” caused by intraperitoneal injection of acetic acid solution and in formalin test. The diclofenac sodium was used as the standard preparation.

There was found a high analgesic activity for the novel compounds of 1-alkyl-3-acetoxy-1,2-dihydro-3H-1,4-benzodiazepine-2-ones series, ED₅₀ indices for analgesic activity are in the dose range from 0.058 to 1.500 mg/kg, all tested compounds by analgesic activity values exceeded the reference preparation, diclofenac sodium.

The obtained data indicate the prospects of a series of the compounds studied in terms of finding and creating new effective analgesic and anti-inflammatory agents.

Key words: 1-alkyl-3-acetoxy-1,2-dihydro-3H-1,4-benzodiazepine-2-ones, analgesia, formalin test.

UDC 616.341-002.1-092.9:618.36-001.18-089.843

K. V. Shepitko, PhD, Associate Professor

MORPHOMETRIC CHARACTERISTICS OF RAT SMALL INTESTINE MUCOSA AFTER SINGLE ADMINISTRATION OF CRYOPRESERVED PLACENTA IN EXPERIMENTAL ACUTE ASEPTIC PERITONEAL INFLAMMATION

HSEEU “Ukrainian Medical Stomatological Academy”, Poltava

Despite the advances of modern surgery, peritonitis remains a topical problem [1; 2]. This is due to the high risk of multiple organ failure. Currently, there are a lot

of studies of peritoneum microcirculation morphological characteristics and parenchymatous organs (liver, kidney, heart) morphological characteristics in acute diffuse

peritonitis [3–5], study of adhesions characteristics after suffering peritoneum inflammation [6]. However, not well studied morphological changes of the intesti-

nal wall in peritonitis, while it is these data will allow a more detailed study of the homeostasis disorders pathogenesis in this pathology. Particularly, deserves a special interest in the study of small intestine morphometric changes in case of peritoneum inflammation. So, now there is a significant complications risk of peritoneum inflammation, it is the part of the small intestine, which in some patients associated with changes in intestinal mucosa against the background of long-term drugs to reduce cardiovascular risk using [7]. In addition, the study of small intestinal mucosa morphometric characteristic in peritoneum inflammation will help to identify new areas of effective pathogenic oriented therapy and prevention of complications.

The paper was aimed at comparison of morphometric parameters of rat small intestine mucosa after single administration of cryopreserved placenta in experimental acute aseptic peritoneal inflammation.

Materials and Methods

The object of the experimental study was the small intestine mucosa, extracted from 50 Wistar sexually mature male rats. General histological and electron microscopic methods of research have been applied.

The animals were assigned to four groups: group I — 5 intact animals; group II — 45 animals, simulated experimental carrageenan-induced acute peritoneal inflammation (intraperitoneally injected with 5 mg once α -carrageenan (Sigma — USA) in 1 ml of saline per animal) and single time administered subcutaneously with cryopreserved placenta concomitant (immunological medicines “Platex placental”, Institute for Problems of Cryobiology and Cryomedicine of the National Academy of Sciences of Ukraine, certificate of state registration N 73408-30020000 from July 9, 2008).

The animals were taken from the experiment under thiopental anesthesia overdose in compliance with the scheduled periods (1-st, 2-nd, 3-rd, 5, 7, 10, 14, 21, 30-th day of the experiment). Pieces of

small intestine were compressed by paraffin and epoxy according to conventional technique. The obtained blocks were sectioned and stained with Van Gieson, hematoxylin-eosin, Hart’s stain (paraffin sections), polychrome stain, methylene blue.

The thickness of duodenum, jejunum and ileum mucosa has been measured. Microscope with BIOREX 3 digital microphotohead (serial number 5604) has been used. Normality tests were applied for all measurement variables in the statistical analysis. Among the measurement variables, for those with a normal distribution, Student’s T-test was used. The statistical significance level was set as $p < 0.05$ for all the tests.

Results

In previous studies we have found that simulation of peritoneum aseptic inflammation was accompanied by significant changes of bowel wall morphometric characteristics, with the maximum expression on the 3-rd day after carrageenin administration into the abdominal cavity. Morphometric characteristics of intestinal wall recovered on the 13-th day of the experiment [8]. Statistical analysis of the duodenum mucosa thickness between the periods of study has shown that during the experiment it was changing (table 1). On the 2-nd day this parameter increased significantly. On the 5-th day this parameter

was maximum high, but no statistical difference has been noted as compared to previous time periods. Starting from the 7-th to 10-th day the mucosa thickness decreased as compared to previous time period ($p > 0.05$). Starting from the 14-th to 30-th day a significant decrease of this parameter has been detected ($p < 0.05$).

The analysis of the duodenum has shown no statistical differences in values of the intact group on the 1-st days ($p > 0.05$); from the 2-nd to 10-th days of the experiment this parameter was significantly higher with peak value on the 5th day, as compared to values from intact group of rats ($p < 0.05$). Starting from the 7-th to 10-th day the thickness of the mucosa reduced insignificantly, as compared to intact group of rats ($p > 0.05$). On the 14–21-st days of the experiment the parameter of mucosa thickness was almost the same as in the intact group and on the 30-th day was within the rates of the latter ($p > 0.05$). Results of the statistical analysis are presented in Fig. 1.

Morphometric analysis of the jejunum mucosa thickness between the time periods of study has shown that during the experiment it was changing. From the 2-nd day this parameter increased significantly ($p < 0.05$). On the 5-th day this parameter was maximum high, but no statistical difference has been noted as compared to previous time periods. Starting from the 7-th to 10-th day the mucosa

Table 1

The Thickness of Ileum Mucosa in Administration of Cryopreserved Placenta Accompanied by Experimental Acute Aseptic Peritoneal Inflammation, $M \pm m$, $n=5$, mkm

| Research term, day | Duodenum mucosa | Jejunum mucosa | Ileum mucosa |
|--------------------|-----------------|----------------|--------------|
| Intact | 1319±23 | 749±9 | 1404±12 |
| 1 | 1318±33 | 758±10 | 1421±14 |
| 2 | 1411±45 | 785±13 | 1484±13* |
| 3 | 1494±40* | 795±11* | 1501±17* |
| 5 | 1521±41* | 803±12* | 1505±15* |
| 7 | 1503±50* | 797±14* | 1481±15* |
| 10 | 1464±40* | 793±12* | 1462±17 |
| 1 | 1373±36 | 768±10 | 1425±14 |
| 21 | 1359±40 | 765±10 | 1419±13 |
| 30 | 1325±33 | 753±13 | 1410±17 |

Note. * — $p < 0.05$ — statistically significant differences between indicators of intact and experimental animals.

thickness decreased as compared to previous time period ($p < 0.05$). Starting from the 14-th to 30-th day a significant decrease of this parameter has been detected ($p < 0.05$).

It has been established that after single administration of cryopreserved placenta in experimental acute aseptic peritoneal inflammation the parameter of jejunum mucosa thickness increased from the 2-nd to 5-th day of the experiment ($p < 0.05$). On the 7–10-th day thinning of mucosa has been. On the 14–21-st days of the experiment the parameter of mucosa thickness was almost the same as in the intact group and on the 30-th day was within the rates of the latter. Results of the statistical analysis are presented in Fig. 2.

Statistical analysis of the ileum mucosa thickness between the time periods of study has shown that during the experiment it was changing. From the 1-st to 2-rd day this parameter increased significantly. On the 5-th day this parameter was maximum high, but no statistical difference has been noted as compared to previous time periods. Starting from the 7-th to 10-th day the mucosa thickness decreased as compared to previous time period ($p > 0.05$). Starting from the 14-th to 30-th day a significant decrease of this parameter has been detected. Results of the statistical analysis are presented in Fig. 3.

The following dynamics has been observed during the analysis of parameters of mucosa thickness between the intact group and group of animals, administered with cryopreserved placenta in experimental aseptic peritoneal inflammation: on the 1-st day the parameter increased but no significant difference between the groups has been noted. From the 2-nd and until 10-th day of the study a significant increase of the parameter has been noted as compared to the group of intact animals ($p < 0.05$). Starting from the 14-th and until 30-th day the parameter changed, and no significant difference has been detected between experimental and intact groups ($p > 0.05$).

Consequently, single subcutaneous administration of cryopreserved placenta in experimental acute aseptic peritoneal inflam-

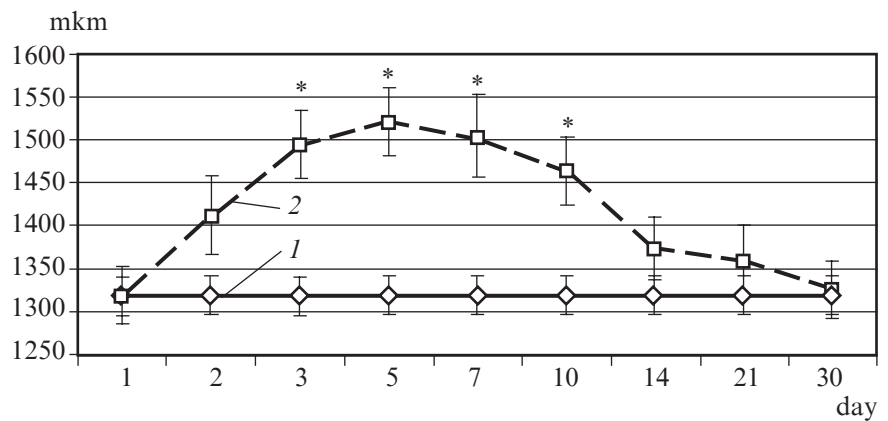


Fig. 1. The thickness of duodenum mucosa in administration of cryopreserved placenta accompanied by experimental acute aseptic peritoneal inflammation. On fig. 1–3 the X-axis — observation day; the Y-axis — mucosa thickness; * — statistically significant differences between indicators of intact and experimental animals ($p < 0.05$); 1 — intact rats; 2 — rats with inflammation and administration of cryopreserved placenta

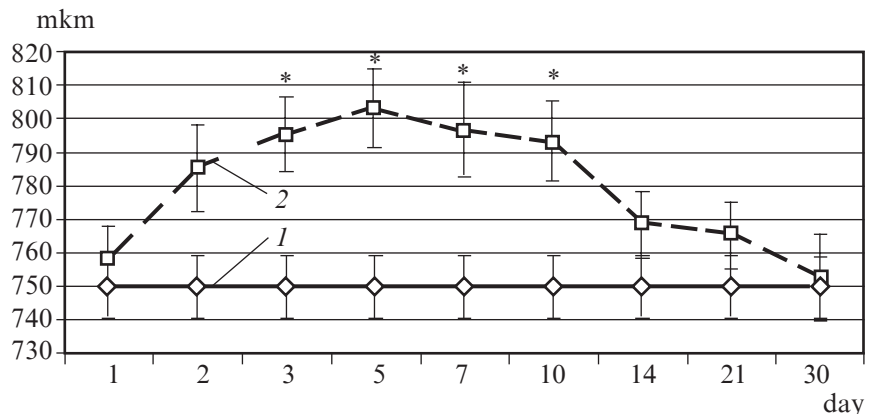


Fig. 2. The thickness of jejunum mucosa in administration of cryopreserved placenta accompanied by experimental acute aseptic peritoneal inflammation

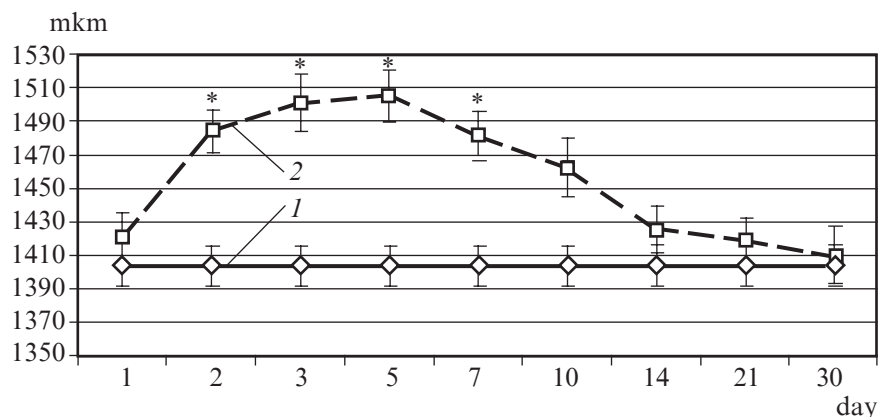


Fig. 3. The thickness of ileum mucosa in administration of cryopreserved placenta accompanied by experimental acute aseptic peritoneal inflammation

mation causes changes of metric parameters of rat small intestine on the 2-rd day with partial restoration on the 7-th day and total restoration on the 14–30-th day.

Thus, the “Platex-placental” promotes more rapid recovery of

the intestinal mucosa to parameters of intact animals in conditions of aseptic inflammation in the abdominal cavity. These data are consistent with those described in the literature of the effects of the “Platex-placental”,

namely the ability to enhance the regeneration of the liver. The use of these medicines will have a positive effect on the recovery of damaged structures, enhance the regeneration of hepatocytes [9]. It is set, that introduction of "Platex-placental" on background of acute experimental gastritis caused increasing of restoration mechanisms in reply to acute inflammation of stomach's mucosa [10]. These effects may be due to the presence in the drug composition of fetoprotein, hormones, interleukins, cytokines, prostaglandins, neurotransmitters, vitamins and minerals that helps to normalize neurological and endocrine status, provide immunomodulation, anti-inflammatory and adaptogenic effects, stimulate reparative processes, normalize proliferation.

Conclusion

It was set that single administration of cryopreserved placenta in experimental acute aseptic peritoneum inflammation helps to restore small intestine mucous membrane thickness up to intact rat's parameters on the 14-th day of experiment. A maximum value of small intestine mucosa reactive thickening (15.3%) was observed on the 5-th day of the ex-

periment. Cryopreserved placenta single subcutaneous injection equally effectively influenced on mucous membrane thickness of different parts of small intestine in experimental acute aseptic peritoneal inflammation.

Prospects for further research. It is planned to study morphological acceleration mechanisms of intestinal mucosa regeneration in aseptic peritoneum inflammation and cryopreserved placenta injection.

REFERENCES

1. Рыбачков В. В. Перитонит / В. В. Рыбачков, К. В. Костюченко, С. В. Маевский. – Ярославль : ЯрМедиа-Груп, 2010. – 305 с.
2. Здзитовецкий Д. Э. Анализ частоты распространенного перитонита и результатов его лечения в многопрофильном стационаре [Электронный ресурс] / Д. Э. Здзитовецкий, Р. Н. Борисов // Современные проблемы науки и образования : электронный научный журнал. – 2012. – № 2. – Режим доступа : <http://wvmv.science-education.ru/102-5771>
3. Гринченко С. В. Морфологическая характеристика микроциркуляторного русла брюшины при разлитом перитоните / С. В. Гринченко // Медицина сьогодні і завтра. – 2013. – № 2 (59). – С. 16–20.
4. Гринченко С. В. Морфологическая характеристика паренхиматозных органов в динамике острого разлитого перитонита / С. В. Гринченко // Kharkiv surgical school. – 2013. – № 4 (61). – С. 45–49.

5. Здзитовецкий Д. Э. Динамика и хирургическая коррекция полиорганной недостаточности у больных распространенным гнойным перитонитом с тяжелыми исходными проявлениями системного воспаления / Д. Э. Здзитовецкий, Ю. С. Винник, Р. Н. Борисов // Вести экспериментальной и клинической хирургии. – 2012. – Т. 5, № 2. – С. 253–257.

6. Морфология формирования послеоперационных брюшинных спаек / В. И. Петлах, В. А. Липатов, Е. С. Елецкая [и др.] // Детская хирургия. – 2014. – № 1. – С. 42–46.

7. Aspirin-induced small bowel injuries and the preventive effect of rebamipide / K. Mizukami, K. Murakami, T. Abe [et al.] // World J. Gastroenterol. – 2011. – Vol. 17, N 46. – P. 5117–5122.

8. Шепітько К. В. Характеристика морфометричних параметрів стінки клубової кишки при одноразовому введенні кріоконсервованої плаценти та асептичному запаленні / К. В. Шепітько // Світ медицини та біології. – 2014. – № 4. – С. 174–178.

9. Лисаченко О. Д. Морфологічні зміни печінки на введення препарату «Платекс-Плацентарний» / О. Д. Лисаченко // Український морфологічний альманах. – 2012. – Т. 10, № 4. – С. 62–63.

10. Білаш С. М. Морфофункціональна перебудова власних залоз фундального відділу шлунка при гострому експериментальному гастриті, введенні препарату «Платекс-Плацентарний» та їх сумісній дії / С. М. Білаш // Український морфологічний альманах. – 2012. – Т. 10, № 4. – С. 8–11.

УДК 616.341-002.1-092.9:618.36-001.18-089.843

К. В. Шепітько

МОРФОМЕТРИЧНА ХАРАКТЕРИСТИКА СЛИЗОВОЇ ОБОЛОНКИ ТОНКОЇ КИШКИ ЩУРІВ ПІСЛЯ ОДНОРАЗОВОГО ВВЕДЕННЯ КРІОКОНСЕРВОВАНОЇ ПЛАЦЕНТИ ЗА УМОВ ЕКСПЕРИМЕНТАЛЬНОГО ГОСТРОГО АСЕПТИЧНОГО ЗАПАЛЕННЯ ОЧЕРЕВИНИ

У роботі досліджено вплив кріоконсервованої плаценти на перебіг асептичного запалення у черевній порожнині. Експериментальні дослідження проведені на 50 статевозрілих щурах, у яких моделювали асептичне запалення шляхом введення карагеніну у черевну порожнину. Частині тварин з експериментальним асептичним запаленням одноразово підшкірно вводили кріоконсервовану плаценту. У дослідних тварин оцінювали динаміку змін морфометричних параметрів товщини слизової оболонки різних відділів тонкої кишки. Уведення кріоконсервованої плаценти на тлі гострого асептичного запалення очеревини сприяє відновленню товщини слизової оболонки тонкої кишки до показників інтактних щурів на 14-ту добу експерименту. Максимальні значення реактивного потовщення слизової оболонки тонкого кишечника на 15,3 % спостерігали на 5-ту добу експерименту ($p < 0,05$). Одноразове підшкірне введення кріоконсервованої плаценти однаково ефективно впливало на товщину слизової оболонки різних відділів тонкого кишечника.

Ключові слова: тонка кишка, слизова оболонка, кріоконсервована плацента, запалення.

UDC 616.341-002.1-092.9:618.36-001.18-089.843

K. V. Shepitko

MORPHOMETRIC CHARACTERISTICS OF RAT SMALL INTESTINE MUCOSA AFTER SINGLE ADMINISTRATION OF CRYOPRESERVED PLACENTA IN EXPERIMENTAL ACUTE ASEPTIC PERITONEAL INFLAMMATION

The influence of cryopreserved placenta in experimental aseptic peritoneal inflammation in rats was investigated. Experiments were carried out on 50 sexually mature male rats. Experimental aseptic peritoneal inflammation was designed by injection of carragenin into abdominal cavity. Parts of animals with experimental aseptic inflammation were injected cryopreserved placenta single subcutaneously. The dynamics of change of morphometric parameters of the thickness of the mucous membrane of the different parts of the small intestine (the duodenum, jejunum, and ileum) was evaluated in experimental animals. It was established that single administration of cryopreserved placenta in experimental acute aseptic peritoneum inflammation helps to restore small intestine mucous membrane thickness up to intact rat's parameters on the 14-th day of experiment. A maximum value of small intestine mucosa reactive thickening (15.3%) was observed on the 5-th day of the experiment ($p < 0.05$). Cryopreserved placenta single subcutaneous injection equally effectively influenced on mucous membrane thickness of different parts of small intestine in experimental acute aseptic peritoneal inflammation.

Key words: small intestine, mucosa, cryopreserved placenta, inflammation.